



PATOLOGIJA MEKIH TKIVA

DR TANJA NENEZIĆ

TUMORI MEKIH TKIVA

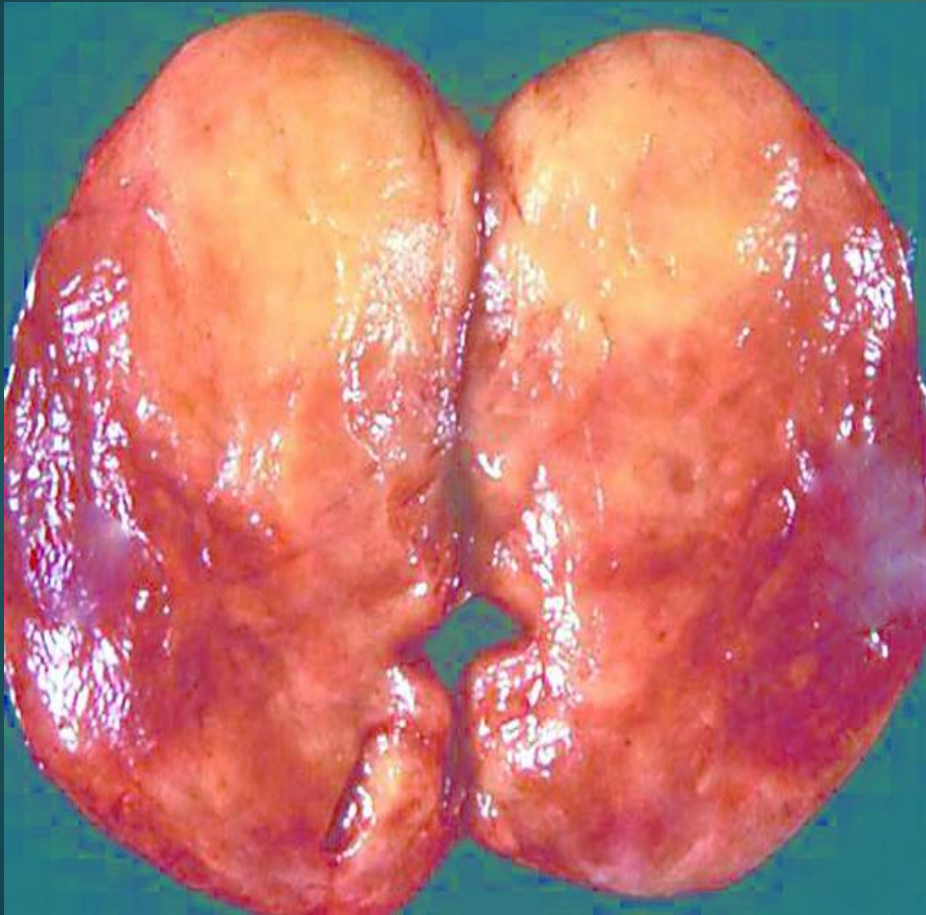- ▶ **Tumori masnog tkiva**

- ▶ **Lipomi**

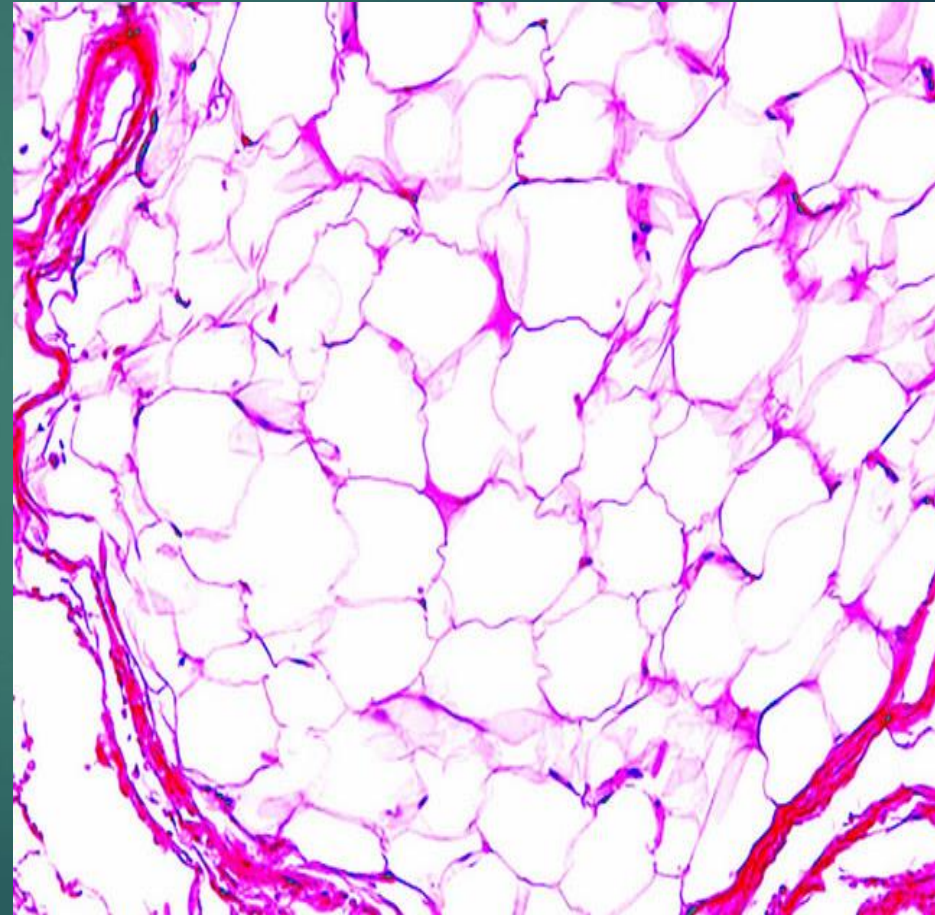
- ▶ **Liposarkom**

LIPOM

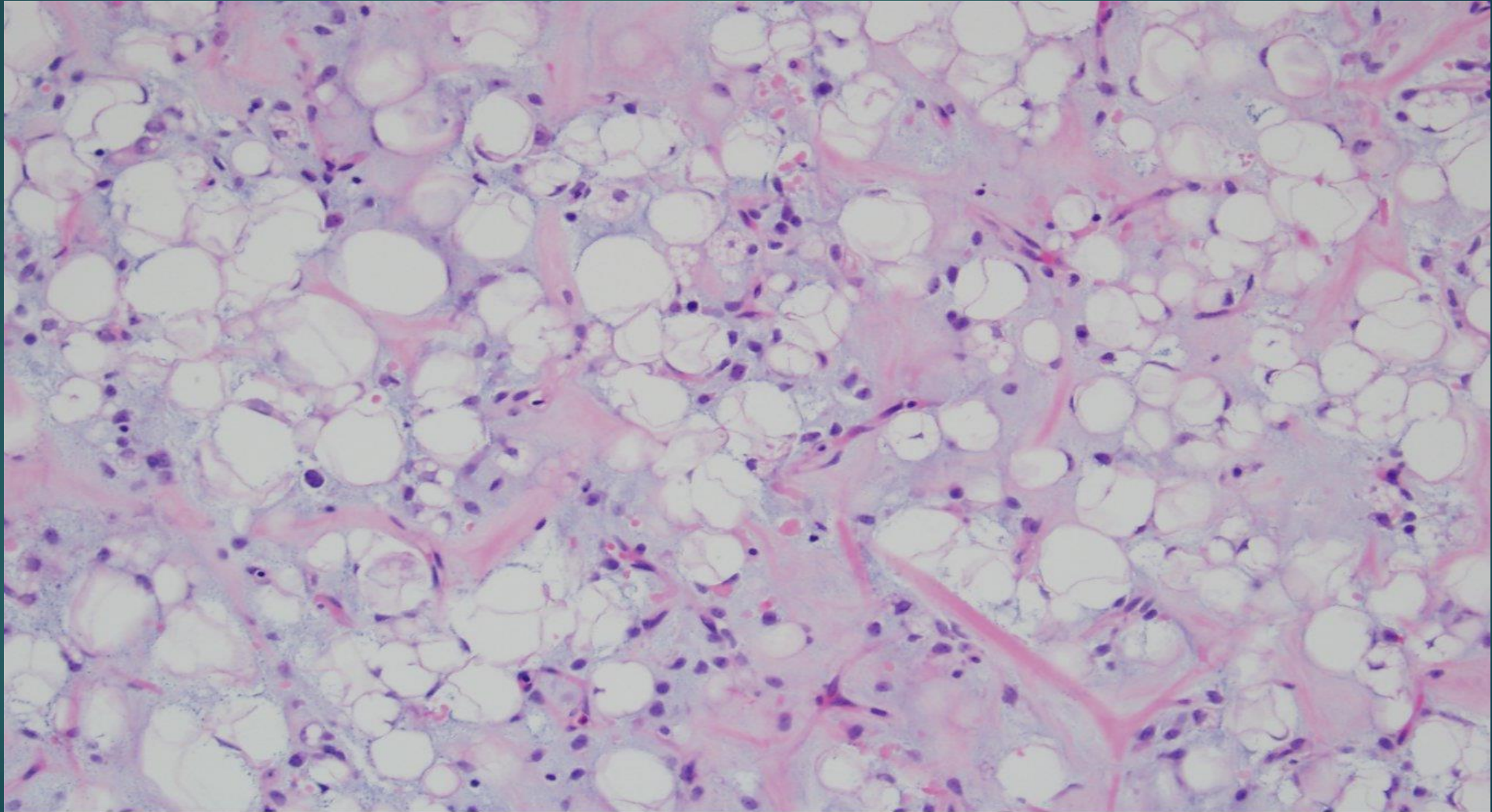
Makroskopski izgled



Mikroskopski izgled



LIPOSARKOM

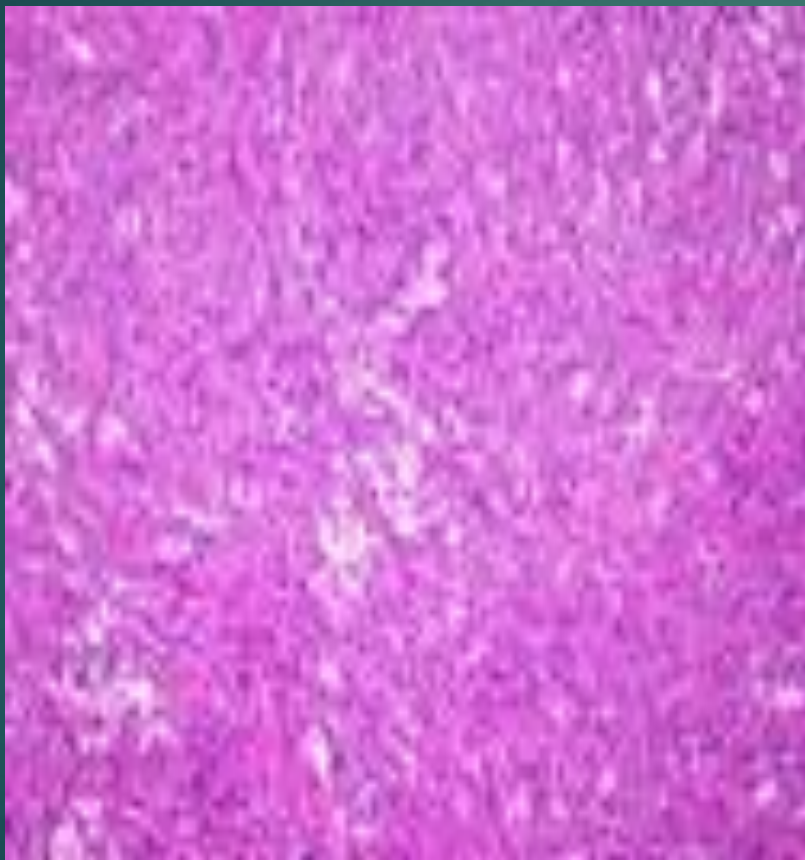


Myxoid liposarcoma: Myxoid background with branching "chicken-wire" capillaries

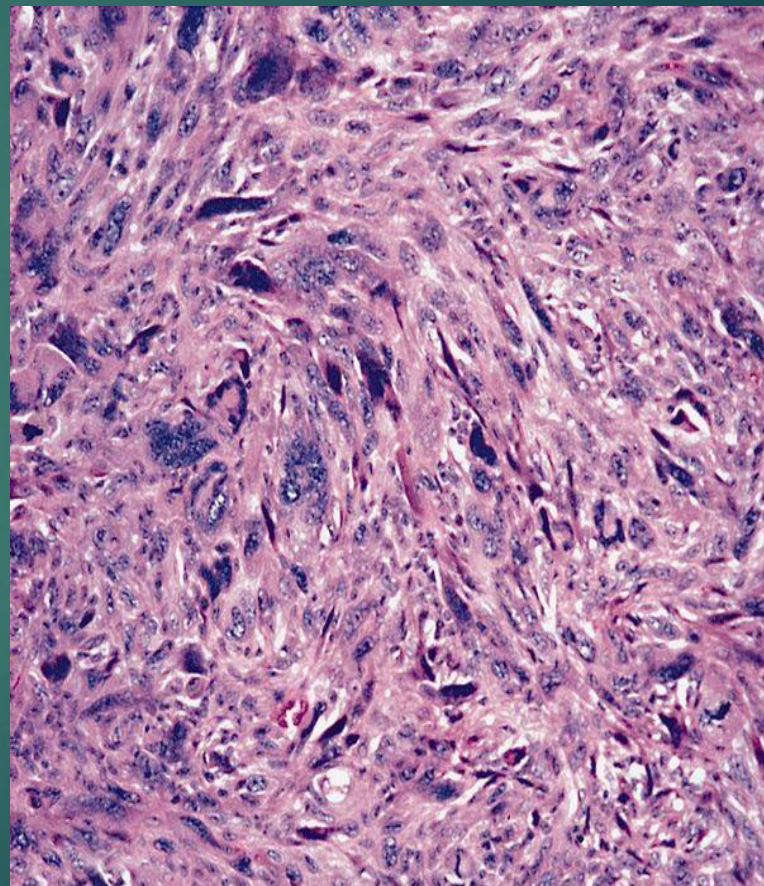
TUMORI I TUMORIMA SLIČNE LEZIJE VEZIVNOG TKIVA

- Nodularni fascitis
- Fibromatoze
 - Povrsinske fibromatoze
 - Duboke fibromatoze
- Fibrosarkom
- **FIBROHISTIOCITNI TUMORI**
 - Fibrozni histiocitom
 - Dermatofibrosarkoma protuberans
 - Maligni fibrozni histiocitom

Fibrozni histiocitom



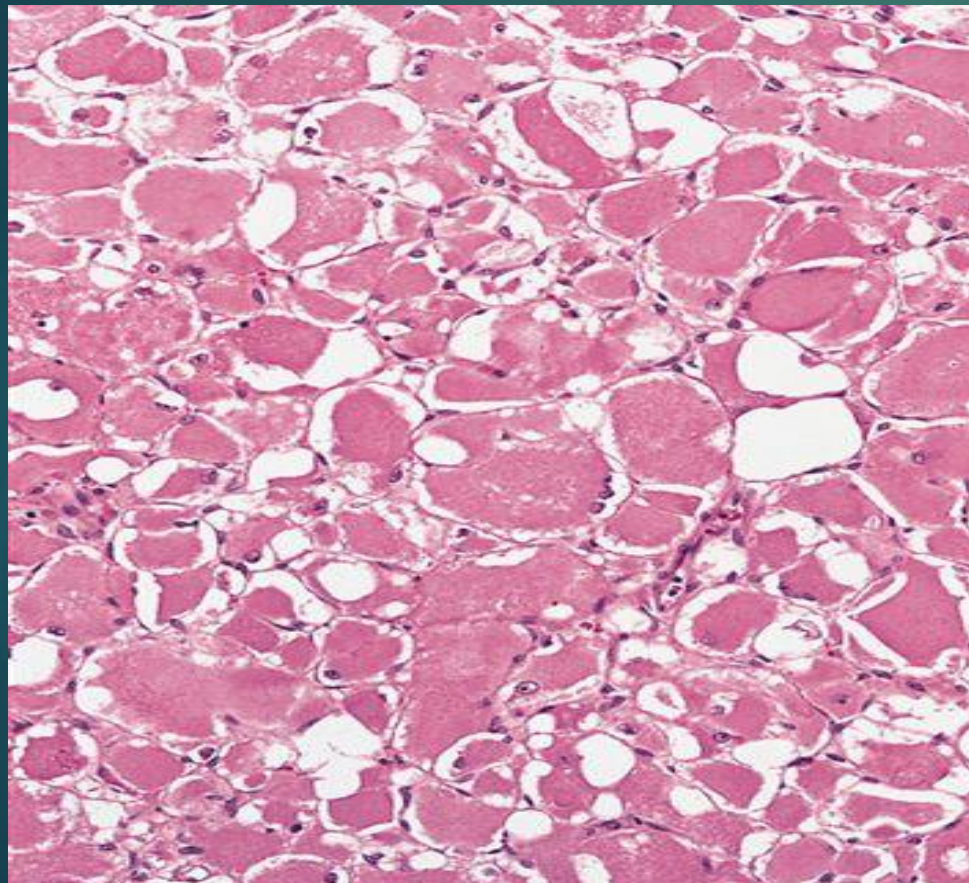
Malignni fibrozni histiocitom



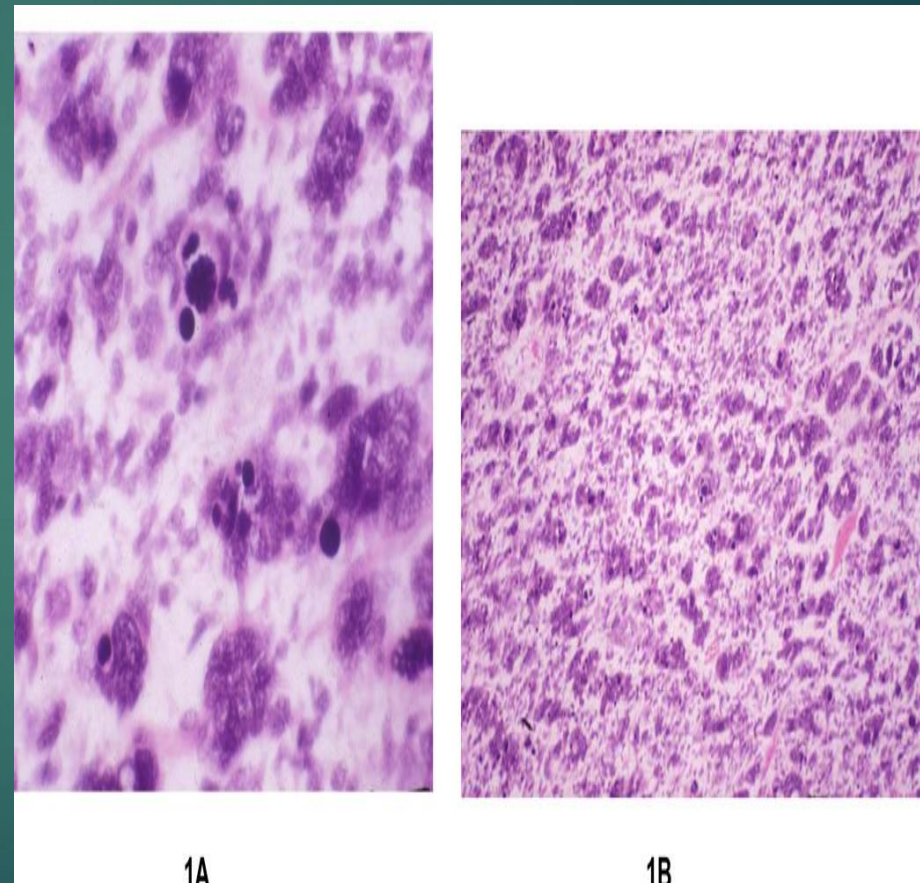
TUMORI SKELETNIH MIŠIĆA

- Rabdomiom
- Rabdomiosarkom

Rabdomiom



Rabdomiosarkom



TUMORI GLATKIH MIŠIĆA

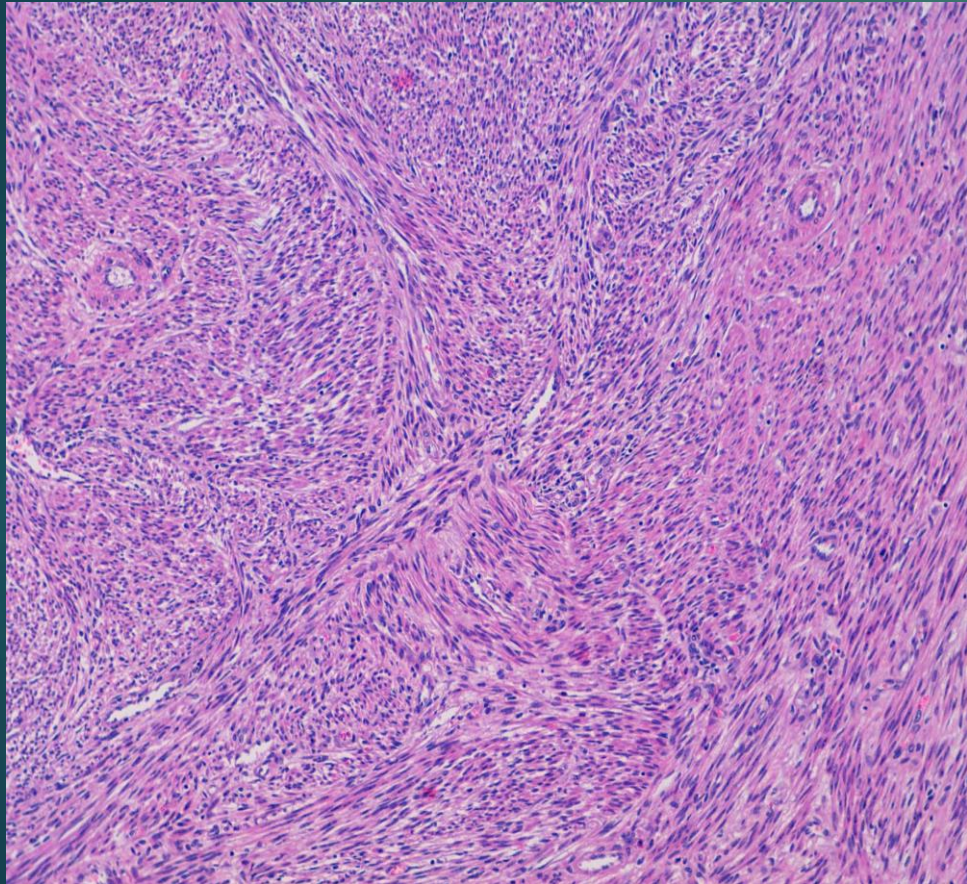
Lejomioma

Tumori glatkih mišića nepoznatog malignog potencijala

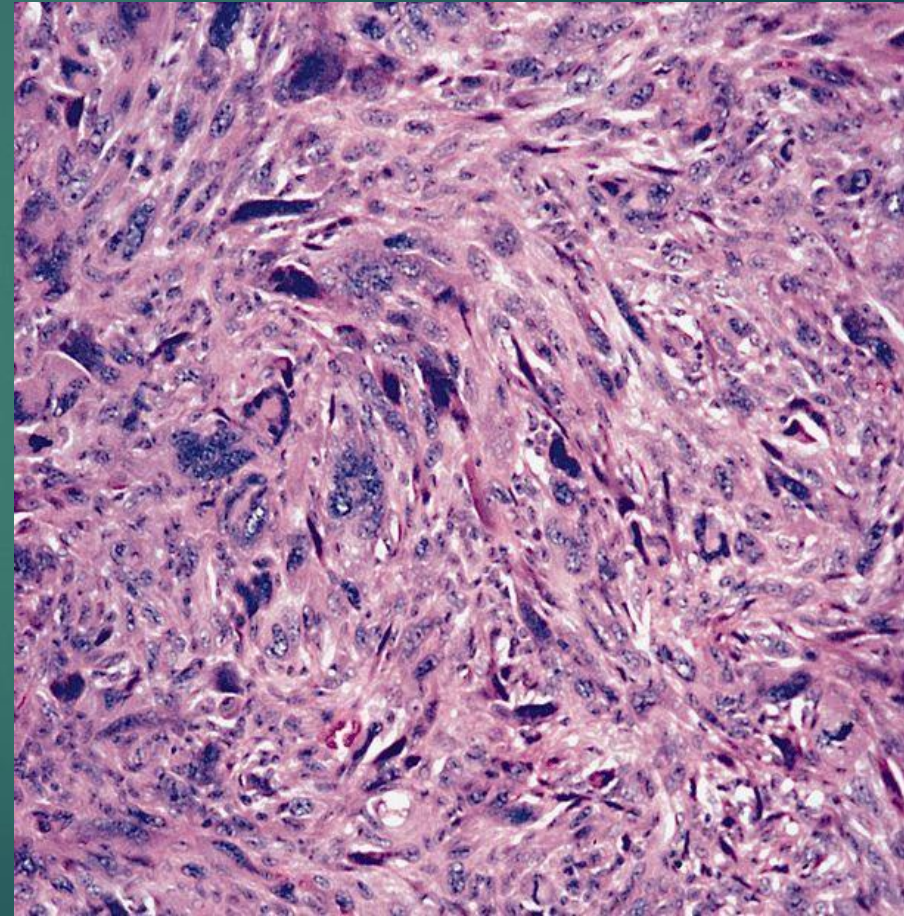
Lejomiosarkom

|

Lejomiom



Lejomiosarkom



VASKULARNI TUMORI

Hemangiom

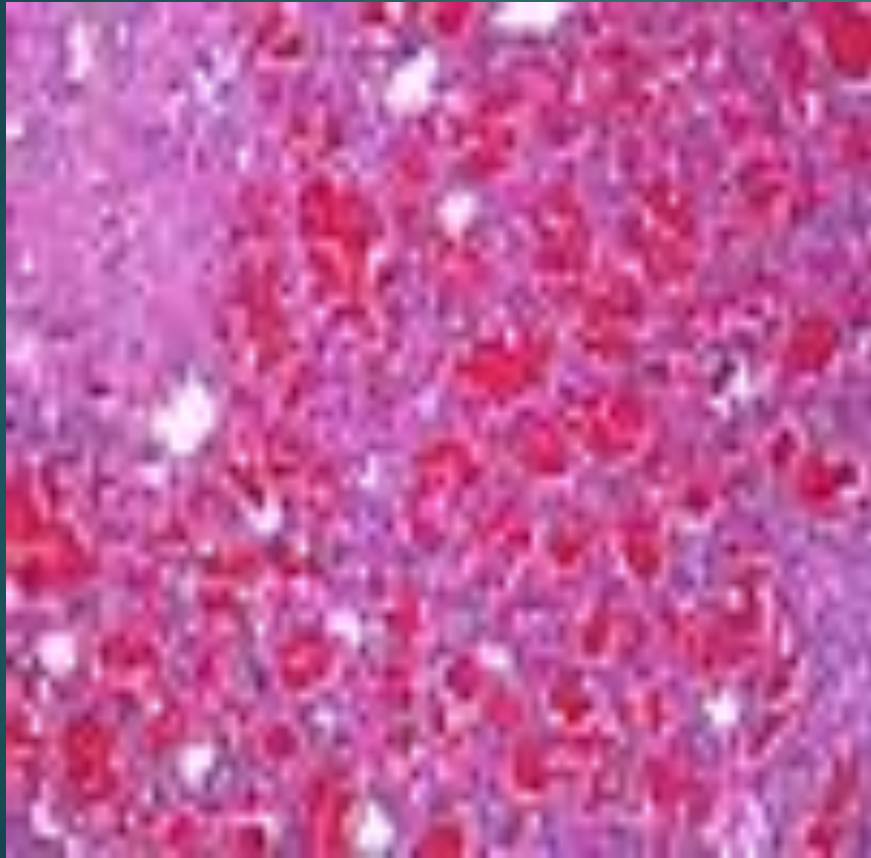
Limfangiom

Hemangioendotelim

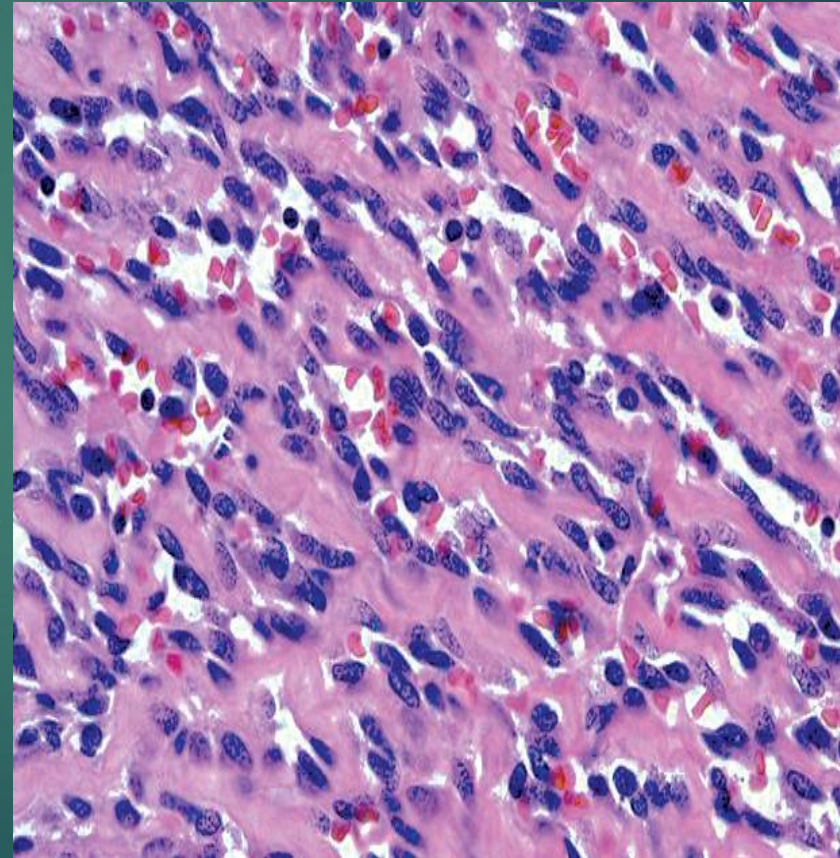
Hemangiopericitom

Angiosarkom

Hemangiom



Angiosarkom



TUMORI PERIFERNIH NERAVA

Neurofibrom

Švanom

Maligni tumor omotača perifernih nerava

Švanom

Maligni tumori omotača perifernih nerava

